



Owner's Copy

**PennHIP Report**

Referring Veterinarian: Dr Dagmar Schouten Email: rpalmer@cedarwoodvet.ca	Clinic Name: Cedarwood Veterinary Hospital Clinic Address: 7644 Gaetz Ave Red Deer, AB T4P 2A8 Phone: (403) 347-2676 Fax: (403) 346-9925
--	--

**Patient Information**

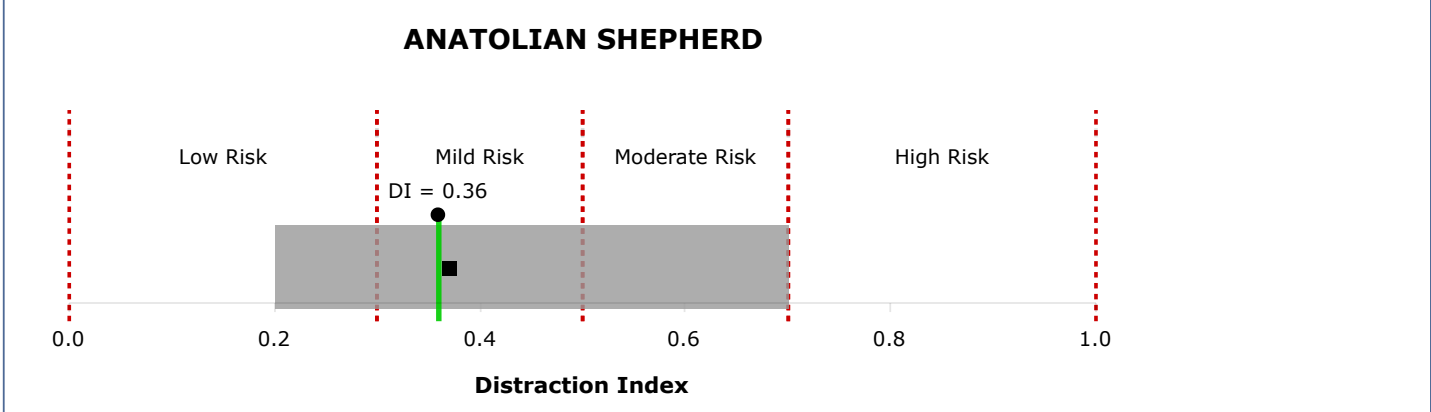
Client: Pearsall, Chantrelle Patient Name: JANE Reg. Name: PennHIP Num: 181793 Species: Canine Date of Birth: 18 Oct 2020 Sex: Female Date of Study: 14 Dec 2022 Date of Report: 16 Dec 2022	Tattoo Num: Patient ID: 209410 Registration Num: Microchip Num: 981020031289674 Breed: ANATOLIAN SHEPHERD Age: 26 months Weight: 115.3 lbs/52.3 kgs Date Submitted: 14 Dec 2022
--	--

**Findings**

Distraction Index (DI): Right DI = 0.31, Left DI = 0.36.  
 Osteoarthritis (OA): **No radiographic evidence of OA for either hip.**  
 Cavitation/Other Findings: No cavitation present.

**Interpretation**

Distraction Index (DI): The laxity ranking is based on the hip with the greater laxity (larger DI). In this case the DI used is 0.36.  
 OA Risk Category: The DI is between 0.31 and 0.49. This patient is at mild risk for hip OA.  
 Distraction Index Chart:



**BREED STATISTICS:** This interpretation is based on a cross-section of 262 canine patients of the ANATOLIAN SHEPHERD breed in the AIS PennHIP database. The gray strip represents the central 90% range of DIs (0.20 - 0.70) for the breed. The breed average DI is 0.37 (solid square). The patient DI is the solid circle (0.36).

**SUMMARY:** The degree of laxity (DI = 0.36) falls within the central 90% range of DIs for the breed. This amount of hip laxity places the hip at a mild risk to develop hip OA. **No radiographic evidence of OA for either hip.**